



Symmetric abnormalities in sulcal patterning in schizophrenia

John G. Csernansky^{a,*}, Sarah K. Gillespie^b, Donna L. Dierker^c, Alan Anticevic^d, Lei Wang^b,
Deanna M. Barch^d, David C. Van Essen^c

^a Department of Psychiatry and Behavioral Sciences, Northwestern Feinberg School of Medicine, 446 E. Ontario – Suite 7-200, Chicago, IL 60611, USA

^b Department of Psychiatry, Washington University School of Medicine, St. Louis, MO, USA

^c Department of Anatomy and Neurobiology, Washington University School of Medicine, St. Louis, MO, USA

^d Department of Psychology, Washington University, St. Louis, MO, USA

ARTICLE INFO

Article history:

Received 14 March 2008

Revised 19 June 2008

Accepted 15 July 2008

Available online 29 July 2008

ABSTRACT

To compare the morphology of the cerebral cortex and its characteristic pattern of gyri and sulci in individuals with and without schizophrenia, T1-weighted magnetic resonance scans were collected, along with clinical and cognitive information, from 33 individuals with schizophrenia and 30 healthy individuals group-matched for age, gender, race and parental socioeconomic status. Sulcal depth was measured across the entire cerebral cortex by reconstructing surfaces of cortical mid-thickness (layer 4) in each hemisphere and registering them to the human PALS cortical atlas. Group differences in sulcal depth were tested using methods for cluster size analysis and interhemispheric symmetry analysis. A significant group difference was found bilaterally in the parietal operculum, where the average sulcal depth was shallower in individuals with schizophrenia. In addition, group differences in sulcal depth showed significant bilateral symmetry across much of the occipital, parietal, and temporal cortices. In individuals with schizophrenia, sulcal depth in the left hemisphere was correlated with the severity of impaired performance on tests of working memory and executive function.

© 2008 Elsevier Inc. All rights reserved.

Introduction

Schizophrenia is thought to have its origins in neurodevelopment (Lewis and Lieberman, 2000). Evidence for this hypothesis includes observations of (i) abnormalities of cognition and social interaction that precede the clinical syndrome and remain relatively unchanged during the course of illness; (ii) prenatal and perinatal insults that increase the risk of developing the illness; and (iii) facial and dermatological anomalies in patients with schizophrenia that reflect aberrant development of the ectodermal germ layer (see Arnold et al., 2005 for review). Moreover, post-mortem studies of the brains of patients with schizophrenia have revealed evidence of abnormal neuronal migration and synaptogenesis (Arnold et al., 2005; Rapoport et al., 2005). Finally, several of the “vulnerability” genes that have been recently associated with schizophrenia play prominent roles in neurodevelopment (Kozlovsky et al., 2002; Toro and Deakin, 2006). In keeping with the hypothesis that schizophrenia is a neurodevelopmental disorder, *in vivo* neuroimaging studies provide evidence of irregularities in the morphology of cerebral gyri (Arnold et al., 2005). For example, Kikinis et al. (1994) compared the pattern of sulci on the lateral surface of the temporal lobe in individuals with and without schizophrenia and reported a bias towards vertically aligned sulcal trajectories in the individuals with schizophrenia.

The study of normal and abnormal configurations of cortical gyri has been greatly facilitated by the development of the tools of computational neuroanatomy (Csernansky et al., 2004). Toga and colleagues developed statistical variability maps for cortical sulci in normal individuals (Thompson et al., 1996, 1997), and using such methods, abnormalities in the normal patterning of sulci have been reported in schizophrenia subjects (Narr et al., 2004). In addition, DeQuardo et al. (1999) and Jou et al. (2005) applied similar methods to characterize abnormalities of sulcal patterning in subjects with schizophrenia subjects and their relatives, respectively. Computational methods have been used to study the patterning of cortical sulci in patients with other neurodevelopmental diseases, including autism (Piven et al., 1990, Courchesne et al., 1993) and William's syndrome (Van Essen et al., 2006; Kippenhan et al., 2005).

Recently, a population-based, surface and landmark-based ‘PALS’ atlas of human cerebral cortex has been developed (Van Essen, 2005) and used to demonstrate cortical folding abnormalities in disease conditions (Van Essen et al., 2006; Nordahl et al., 2007). The PALS atlas utilizes a surface-based registration process to compare groups of individuals with and without neuropsychiatric disease, and to assess the hemispheric symmetry of group differences. In the present study, we used the PALS atlas and associated surface-based registration methods to compare the pattern of cortical sulcal depths in individuals with and without schizophrenia matched for age, gender and parental socioeconomic status. We found a bilateral difference between groups in the depth of the cortex in the parietal operculum.

* Corresponding author. Fax: +1 312 926 8080.

E-mail address: jgc@northwestern.edu (J.G. Csernansky).

Further, in the subjects with schizophrenia, a measure of sulcal depth in this region of the left hemisphere was associated with the severity of cognitive deficits.

Materials and methods

Participants

Thirty-three individuals with schizophrenia and 30 healthy individuals, matched in age, gender, race, and parental socioeconomic status, gave written informed consent for participation in this study after the risks and benefits of participation were explained to them. The demographic and clinical characteristics of these groups are summarized in Table 1. The diagnosis of each individual was based on criteria from the Diagnostic and Statistical Manual for Mental Disorders—Fourth Edition (DSM-IV) (American Psychiatric Association, 1994) and determined by the consensus of a research psychiatrist who conducted a semi-structured interview and a research assistant who used the Structured Clinical Interview for the DSM-IV (SCID-IV) (First et al., 1995). No individual had an unstable medical or neurological disorder, a head injury with loss of consciousness, nor did any meet DSM-IV criteria for substance abuse or dependence for at least three months prior to their participation in the study. Healthy individuals were also excluded if they had first-degree relatives with a psychotic disorder. All but three subjects with schizophrenia and three healthy individuals were right-handed.

The large majority of the individuals with schizophrenia were treated with atypical antipsychotic drugs at the time of their participation in the study, and in all individuals with schizophrenia, their symptoms had remained unchanged for at least two weeks prior (Rastogi-Cruz and Csernansky, 1997) to their participation in the study. The severity of psychopathology was assessed using the Scale for the Assessment of Positive Symptoms (SAPS) (Andreasen, 1984) and the Scale for the Assessment of Negative Symptoms (SANS) (Andreasen, 1983). Using the factor loadings reported by Andreasen and colleagues for these scales (Andreasen et al., 1995), we computed scores for three dimensions of psychopathology (i.e., negative symptoms, psychosis and thought disorganization).

Cognitive function was assessed in each subject using a battery of neuropsychological tests. Raw scores from individual neuropsychological tests were standardized (i.e., converted to z-scores) using the mean and standard deviation values computed across a population of 216 subjects (representing all individuals with schizophrenia and comparison subjects who have participated in research studies at our research center). These z-scores were then averaged to yield summary scores for four broad cognitive domains – working memory, episodic memory, executive function, and attention.

Table 1
Participants demographic and clinical information

Variables (mean +/- SEM [range])	Schizophrenia	Comparison
N	33	30
Age	26.5(9.2[17.0–49.6])	26.1(10.8[14.6–49.7])
Gender (male/Female)	24/9	20/10
Race (Caucasian/African-American)	21/12	25/5
Parental SES	3.2(1.4[1–5])	2.9(0.8[1–4])
Age of illness onset	19.1(5.5[5.3–36.2])	Not applicable
Duration of illness (years)	7.4(9.5[0.2–36.4])	Not applicable
Positive symptoms score	2.00(1.48[0.0–5.0])	Not applicable
Negative symptoms score	1.89(0.85[0.5–3.5])	Not applicable
Thought disorganization score	1.09(0.75[0.0–3.67])	Not applicable
Working memory score*	-0.3(0.82[-2.26–0.98])	0.38(0.62[-0.96–1.38])
Episodic memory*	-0.57(0.75[-1.95–0.94])	0.63(0.67[-1.28–1.35])
Executive function score*	-0.36(0.76[-2.79–0.49])	0.41(0.44[-0.36–1.49])
Crystallized IQ*	8.84(3.92[1.00–18.00])	12.19(3.32[5.00–19.00])

* Based on 33 Schizophrenia subjects and 27 comparisons.

Image collection

Magnetic resonance (MR) scans were collected using a Magnetom SP-4000 1.5-Tesla Siemens imaging system with a standard head coil and four repetitions of an T1-weighted MPRAGE sequence (voxel resolution: 1 mm × 1 mm × 1.25 mm, TI:20 ms, TD:500 ms, TR:9.7 ms, TE:4.0 ms, FLIP:10, Matrix:256 × 256, Rect. FOV: 7/8, Partitions:128, Time=13 min and 12 s for each set of two repetitions). For each individual, the first scan was registered to 711-2Y stereotaxic space using a 12-parameter affine transform; the remaining three MPRAGE images were then registered to the first and transformed to the same stereotaxic space through a single, composites interpolation (Buckner et al., 2004). This procedure yielded an average image in standard stereotaxic space that is similar, but not identical to, Talairach space (Talairach and Tournoux, 1988; see Van Essen and Dierker, 2007). Prior to image processing, MR scans were coded and stripped of all personal identifiers and diagnostic group information. The modal interval between the time of clinical and neurocognitive assessment and image collection was 21 days.

Tissue segmentation and construction of a fiducial cortical surface

The realigned MR datasets were imported into Caret 5.5 software (<http://brainmap.wustl.edu/caret/>) to generate cortical surface reconstructions. Using the SureFit algorithm (Van Essen et al., 2001; see <http://brainvis.wustl.edu/caret/>), a fiducial surface was generated running midway through the cortical mantle, approximating the trajectory of cortical layer 4. Using the cortical mid-thickness avoids biases in under-representing gyral surface area and over-representing surface area of sulcal fundi that occurs when using the gray-white interface that is used in many other segmentation algorithms. An automated error-correction algorithm followed by manual editing was used to correct errors in the initial segmentation. One rater (SKG) performed the segmentations of the left and right hemispheres of 20 control subjects and 23 schizophrenia subjects. Another rater (AA) performed the remaining segmentations. The 'raw' surface generated from the corrected segmentation was slightly smoothed to create a final fiducial cortical surface. A representation of the cerebral hull – that is, the outer extent of the cerebral mantle that did not extend into sulci – was generated by dilation and erosion operations applied to the cortical segmentation (Van Essen, 2005) and a cerebral hull surface was then generated by tessellation of the segmentation. Finally, a sulcal depth map was created for each hemisphere in each individual by measuring the Euclidean distances from each node on the fiducial surface to the nearest point on the cerebral hull surface. Sulcal depth computed in this way provides an objective measure of cortical shape characteristics that can be quantified within and across groups (Van Essen, 2005; Van Essen et al., 2006). The possibility that a group difference in cortical thickness would introduce a confound in tests for sulcal depth differences warrants consideration, but it is unlikely to impact our findings (see Discussion).

Surface-based registration

The fiducial cortical surface of each hemisphere was inflated, flattened, and mapped to a spherical configuration, and processed by multi-resolution morphing to reduce areal distortions. To register each individual hemisphere to a common target atlas, a set of six highly consistent anatomical landmarks (i.e., the central sulcus, calcarine sulcus, sylvian fissure, anterior half of the superior temporal gyrus, and the dorsal and ventral segments of the medial wall) was drawn on each flattened hemisphere by one rater (SKG) using criteria previously described (Fig. 1; Van Essen (2005); see http://brainvis.wustl.edu/help/landmarks_core6/landmarks_core6.html). These core landmarks were then used to register the individual spherical surface of both left and right hemispheres to the standard spherical mesh of

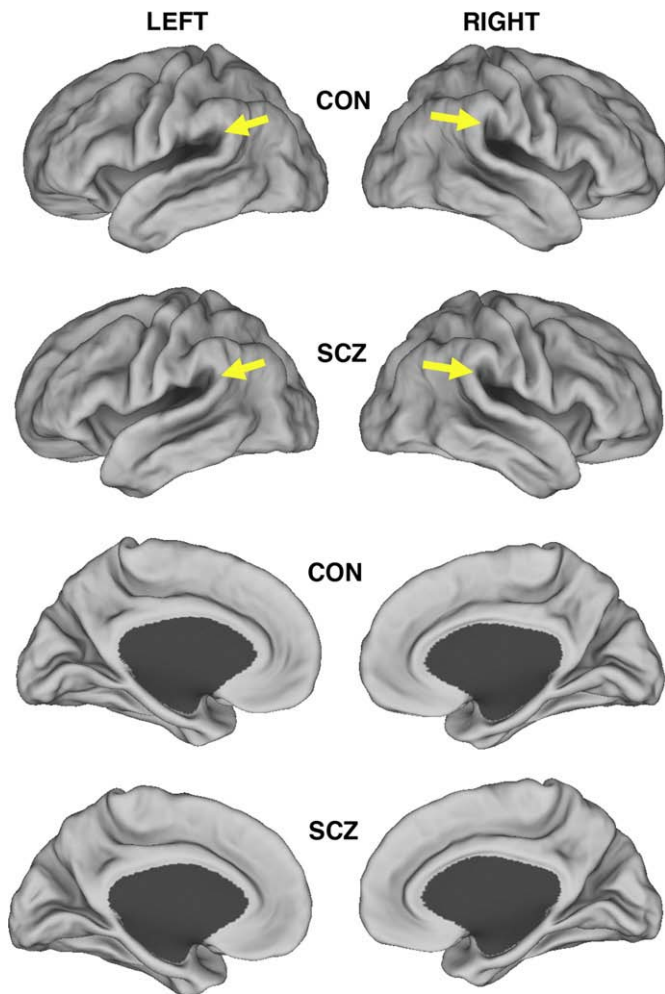


Fig. 1. Lateral (first and second rows) and medial (third and fourth rows) views of the average fiducial cortical surfaces of schizophrenia subjects (second and fourth rows) and healthy individuals (first and third rows). Arrows point to the dorsal ramus of the Sylvian Fissure, where the two surfaces differ in shape. These and other subtle differences were studied by sulcal depth analyses in subsequent figures.

the PALS-B12 atlas, whose population-average landmarks were generated from the right hemispheres plus mirror-flipped left hemispheres of 12 healthy young adults (Van Essen, 2005). After registration was complete, individual fiducial cortical surfaces were resampled into a standard mesh (Saad et al., 2004) containing 73,730 surface nodes. Average fiducial cortical surfaces were computed separately for the groups of schizophrenia and control subjects by determining the geometric mean for each node of the individual standard-mesh fiducial surfaces for each group.

Comparisons between the left and right hemisphere data sets is greatly facilitated by the use of standard-mesh surfaces and registration to a target atlas that reflects shape characteristics of left and right hemispheres in a population of normal individuals.

Data analysis

Sulcal depth maps across subjects within each group were averaged node-by-node to create average sulcal depth maps. A t -statistic map was generated by calculating a value (assuming unequal variance) for each node in the schizophrenia and control groups. Two statistical methods, a *cluster size analysis* and an *interhemispheric symmetry analysis*, were used to test for significant sulcal depth differences between the schizophrenia and control groups, while addressing the issue of multiple comparisons (Van Essen et al., 2006).

The cluster-size analysis tested for clusters in the left or right hemisphere that surpassed a minimum surface-area threshold. The interhemispheric symmetry analysis tested for clusters that were present in corresponding locations in both hemispheres.

For the cluster size analysis, the depth t -statistic map was generated for each hemisphere using a threshold of $t > 2.66$ ($p < .01$, two-tailed with 61 degrees of freedom). A permutation analysis similar to the suprathreshold cluster test described by Nichols and Holmes (2002) established the minimum surface area required for a cluster to reach statistical significance, providing strong control over family-wise error rate (i.e., the probability of a single false positive cluster). Group memberships were permuted 10,000 times; for each iteration, a t -map was generated and surface area of the largest cluster determined. Both actual and permuted t -map areas were corrected for distortions involved in mapping from individual fiducial surfaces to the average fiducial surface. Clusters on the actual t -map whose area exceeded the smallest of the $.05$ (α) $\times 10,000$ (iterations) = 500 largest clusters were considered significant.

For the interhemispheric symmetry analysis, a t -correlation map was generated by multiplying the t -value at each node of the left hemisphere with the t -value of the corresponding node in the right hemisphere. The t -correlation map was thresholded at $|5.32|$ (twice the single hemisphere threshold), and the surface area of each resulting positive and negative cluster was determined. A higher threshold than $|2.66|$ is appropriate because the values represent the product of two t -statistics but a value lower than $2.66^2 = 7.1$ is appropriate in order to test for clusters that are biologically plausible in spatial extent. Permutation analysis (10,000 iterations of shuffled t -maps) determined the cutoff surface area for statistically significant clusters. To test whether interhemispheric correlations occurred systematically across the entire hemisphere, the fraction of nodes having positive t -correlation values was computed, and was tested for significance using a permutation analysis (10,000 iterations of shuffled t -maps).

Since the anatomical basis of those differences are not discernible from the t -maps alone (Nordahl et al., in press), we mapped the gyral regions associated with statistically significant depth differences (Dierker et al., 2007).

The relationships between the clinical variables and structural measures were examined only in the individuals with schizophrenia, while the relationships between the cognitive domain variables and structural measures were examined both in the individuals with and without schizophrenia. After the testing of specific hypothesized relationships, all others were examined *post-hoc*. All correlations were estimated using non-parametric statistics (Spearman's ρ), and the significance of the *post-hoc* correlations were corrected for multiple comparisons.

Data access

These data are available for further visualization and analysis via the SumsDB database— <http://sumsdb.wustl.edu/sums/directory.do?id=6650505>. These include animations that morph between the schizophrenia and control average fiducial surfaces.

Results

Group differences

Fig. 1 shows the average fiducial cortical surfaces generated for the schizophrenia and control groups. Visual inspection of these representations suggested subtle group differences in sulcal patterning. For example, the posterior ramus of the Sylvian fissure was oriented more vertically in the left hemisphere of the schizophrenia subjects than in the healthy individuals, and correspondingly, the supramarginal gyrus was more dorsal in the schizophrenia subjects than in the healthy

individuals (yellow arrows in Fig. 1). The opposite pattern is evident in the right hemisphere. In addition, greater symmetry in the posterior ramus of the Sylvian fissure was observed in the subjects with schizophrenia than in the healthy individuals.

In Fig. 2, the *t*-statistic maps are displayed on lateral views of the very inflated PALS atlas surface (top row) and on lateral and medial views of the inflated atlas surface (middle and bottom rows). The cortex was deeper on average in the schizophrenia subjects in many regions (cooler colors) but was deeper on average in the healthy individuals (warmer colors) over a slightly larger extent (54% of surface nodes on left, 55% on the right). In most regions, the *t*-statistic values were small in magnitude, but there was a prominent cluster (red) in the parietal operculum of each hemisphere (arrows, left and middle panels). Cluster size analysis demonstrated that these two clusters (with sulcal depth deeper in the healthy individuals) were significant in both the left ($p=0.03$) and right ($p=0.05$) hemispheres. Moreover, the sulcal depth abnormality was highly significant ($p=0.001$) when tested by the interhemispheric correlation analysis (right panel). The group differences in average sulcal depth were small in magnitude (1.36 mm on average in the left hemisphere and 1.38 mm on the right). High statistical significance was attained at this location because it is a region of low variability in sulcal depth (Van Essen, 2005) and the test for interhemispheric symmetry is notably sensitive to modest group differences (Van Essen et al., 2006).

Visual inspection of the *t*-statistic maps for the left and right hemispheres also revealed many correspondences across the two hemispheres, particularly in posterior regions. For example, average sulcal depth was deeper in the schizophrenia subjects along most of the fundus of the superior temporal sulcus (STS) and in several symmetrically located regions in medial aspects of the two hemispheres. A comparable symmetry was evident in regions such as the parieto-occipital sulcus (POS), where average sulcal depth was deeper in the healthy individuals. The interhemispheric correlation maps (Fig. 2, right panels) confirm that these correspondences are

consistent over most of posterior cortex, as evidenced by the overall prevalence of warmer over cooler colors (57.7% of nodes having positive *t*-correlation values; average *t*-value=0.22 after excluding the extreme 4%). A permutation analysis (see Materials and methods) demonstrated that these correlations were very unlikely to have occurred by chance ($p=.0052$), and suggests a widespread pattern of consistently symmetric group differences in sulcal depth that are of both polarities (i.e., bilaterally deeper on average in the schizophrenia subjects in some regions, but bilaterally deeper in the healthy individuals in other regions).

Fig. 3 shows the location of the sulcal depth abnormality (blue, from the interhemispheric correlation analysis) and the nearby gyral region used in computing sulcal depth (yellow; see Materials and methods) displayed on three surface configurations: i) the average fiducial cortical surface of the comparison group (top row), ii) the average fiducial cortical surface of the schizophrenia group (second row), and iii) the PALS_B12 inflated surface (third row). In relation to architectonic subdivisions, the sulcal depth abnormality occupies almost all of cortical area OP2 and part of OP1 [based on the opercular parcellation of Eickhoff et al. (2006a,b)]. The associated gyral region near the junction of the angular and postcentral gyri occupies part of area OP1.

The bottom panel of Fig. 3 shows a coronal slice through the relevant portion of the parietal operculum, with the average fiducial surface contours for each group (red for schizophrenia, black for controls) overlaid on the 711-2Y average MRI volume. The average surface for the schizophrenia subjects is positioned more laterally (and thus closer on average to the cerebral hull) near the lip of the Sylvian fissure (yellow arrow on left) and near its fundus (dorsal insula, green arrows on left and right). Furthermore, in the intervening opercular region (black arrows), corresponding surface nodes were displaced slightly laterally in the average schizophrenia fiducial surface compared to the average fiducial surface of the healthy individuals.

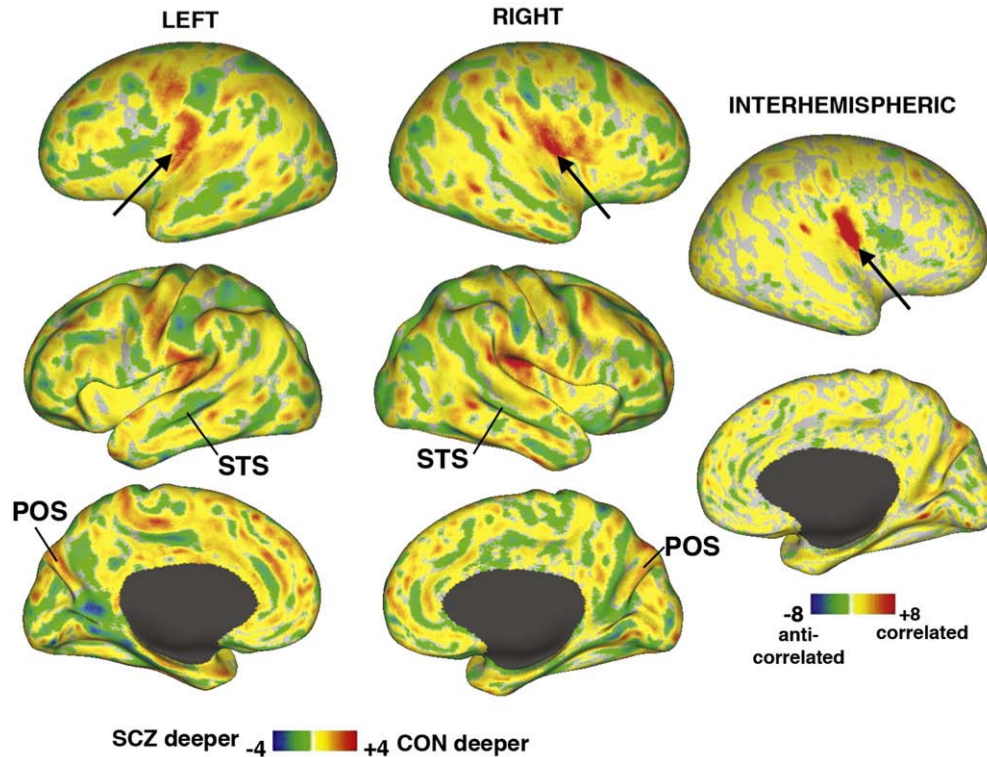


Fig. 2. Lateral and medial views of *t*-statistic maps of group differences in sulcal depth, displayed on very inflated lateral views and on inflated lateral and medial views of the PALS atlas surface (left and middle columns). Control—deeper regions are indicated in yellow and red; schizophrenia—deeper regions are shown in green and blue. Far right panels display interhemispheric correlation maps on the very inflated lateral view and inflated medial view. See text for statistical results.

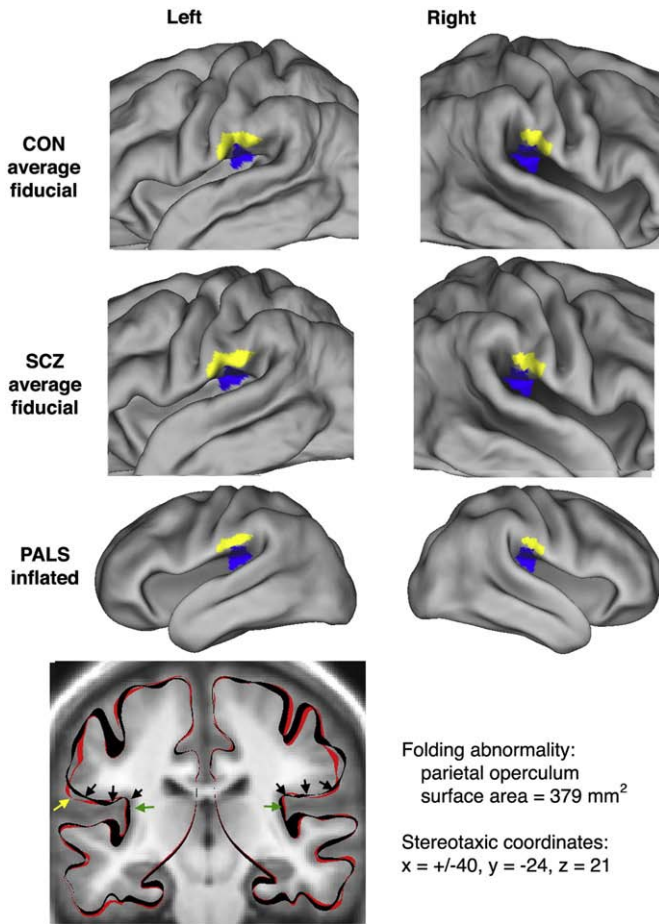


Fig. 3. A significant group difference in sulcal depth observed as a cluster of nodes in the parietal operculum. This cluster is displayed on the average fiducial cortical surface of the healthy individuals (top row); the average fiducial cortical surface of the schizophrenia subjects (second row); and the inflated PALS-B12 surface (third row). The significant sulcal depth abnormality is shaded blue; the associated gyral region is shaded yellow. In the bottom panels, average fiducial cortical contours from the subjects with schizophrenia subjects (red) and healthy individuals (black) are shown superimposed on the 711-2Y atlas target volume. The average fiducial surface is visibly more lateral (closer to the cerebral hull) near the lip of the Sylvian fissure (yellow arrow) on the left and in the insula on both sides (green arrow). The depth difference was highly significant along a bilateral swath of operculum (black arrows).

Clinical and cognitive correlations

The functional significance of the group difference in sulcal depth was evaluated by calculating correlations between the average depth of the fiducial cortical surface in this region in each subject and selected measures of psychopathology and cognition. Because of the association of the left angular and postcentral cortical gyri with language and the interpretation of verbal information (Marslen-Wilson and Tyler, 2007), we hypothesized that there would be a relationship between sulcal depth in the vicinity of the left parietal operculum and the severity of thought disorganization as well as deficits in working memory and executive function in the schizophrenia subjects. We did not expect to find similar relationships related to sulcal depth in the vicinity of the right parietal operculum, nor any relationships between anatomic and cognitive measures in the healthy individuals. We found significant correlations between sulcal depth in the vicinity of the left parietal operculum and measures of working memory and executive function (i.e., values more disparate from the average value of the healthy group were correlated with more severe deficits) (see Fig. 4, panels a and b). Post hoc, we found two correlations of moderate size between the average depth of the fiducial

cortical surface in the vicinity of the right parietal operculum and the severity of thought disorganization and negative symptoms in the schizophrenia group (see Fig. 4, panels c and d). However, these correlations did not remain significant after correcting for multiple comparisons. As predicted, no significant relationships between anatomic and functional measures were found in the comparison subjects.

Discussion

The primary objective of this study was to compare the morphology of the cerebral cortex and its characteristic pattern of gyri and sulci in individuals with schizophrenia and healthy individuals, matched for gender, age and parental socioeconomic status. We identified a bilateral sulcal depth abnormality in the parietal operculum of individuals with schizophrenia. However, the results do not reveal whether the underlying structural abnormalities are in cortical gray matter, in underlying white matter, or even in nearby subcortical nuclei. Notably, the observed sulcal depth difference in the individuals with schizophrenia was slightly posterior (12 mm center-to-center difference) to a bilateral sulcal depth abnormality found in individuals with high-functioning autism (Nordahl et al., 2007).

An important methodological issue is whether our measures of sulcal depth might have been confounded by group differences in average cortical thickness. Several studies have reported cortical thinning in schizophrenia (Kuperberg et al., 2003; Narr et al., 2005; Narayan et al., 2007). However, the reported regions of thinning do not overlap with the parietal operculum sulcal depth abnormalities reported here. Also, the magnitude of the reported thinning is less than 0.15 mm on average (Kuperberg et al., 2003), about 10% of the

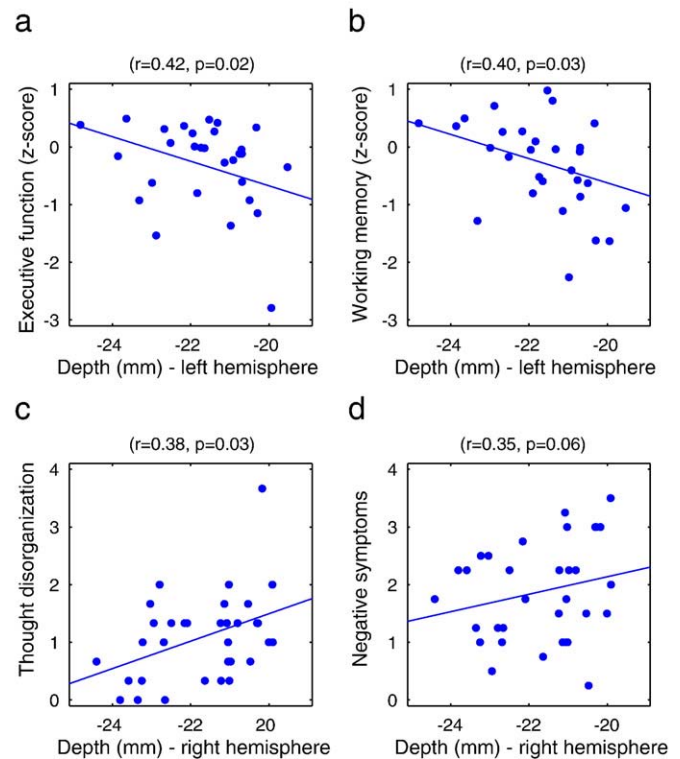


Fig. 4. Scattergrams of correlations between sulcal depth within the cluster of nodes where a significant group difference was found and measures of neurocognitive function (panel a – executive function; panel b – working memory) and psychopathology (panel c – thought disorganization; panel d – negative symptoms). Less negative depth values (i.e., more shallow sulcal depth) were more disparate from the average depth value of the healthy comparison group. The correlations noted in panels c and d were found post-hoc, and the statistical significance of these correlations did not survive correction for multiple comparisons.

depth abnormality we observed. Finally, our sulcal depth analysis would be impacted only if thinning occurred in one region (e.g., gyral) and not the other (e.g. sulcal). Thus, group differences in thickness do not account for our findings.

It is also unlikely that our results are attributable to group differences in the quality of sulcal alignment achieved by our registration method. Using the same dataset and surface-based registration method, Anticevic et al. (2008) demonstrated equally good alignment precision for five identified sulci in the schizophrenic and healthy control groups.

To assess the functional significance of this finding, we correlated mean sulcal depth in the region of interest with measures of psychopathology and cognition in the individuals with schizophrenia. Because of the involvement of the parietal operculum, or inferior parietal gyrus, and the arcuate fasciculus that underlies it, particularly in the left hemisphere, in working memory and language comprehension (Mesulam, 1998; Marslen-Wilson and Tyler, 2007), we hypothesized that correlations would occur between the magnitude of the anatomical change in the left hemisphere and the severity of deficits in working memory, executive function, and thought disorganization in the individuals with schizophrenia, but not necessarily in the healthy individuals. The predicted correlations between the left hemisphere neuroanatomical measure and working memory and executive function were found in the subjects with schizophrenia. Also, in a subsequent exploratory analysis of the schizophrenia subjects, we found modest correlations between the magnitude of the anatomical change in the right hemisphere and the severity of thought disorganization and negative symptoms. However, these latter correlations were not predicted *a priori*, and their statistical significance did not survive correction for multiple comparisons. As expected, similar correlations were not found within the group of healthy individuals, and suggest that the observed relationships are specific in some way to the disease state of schizophrenia.

The observed correlations between neuroanatomic and cognitive measures are consistent with disturbances of functions usually associated with the parietal operculum. The inferior parietal cortex is classed among other heteromodal association cortices, and is an important component of the network of structures that supports working memory (Zhou et al., 2007), while the underlying arcuate fasciculus is implicated in language comprehension (Mesulam, 1998; Marslen-Wilson and Tyler, 2007). Also, the parietal operculum and the anterior cingulate cortex are part of a network that subserves the emotional perception of somatic sensations (Shibasaki, 2004). Thus, the changes in the conformation of the cortical mantle observed in the individuals with schizophrenia might be associated with any of these cognitive processes.

Compared to other regions of the cerebral cortex, the parietal cortex has received relatively little attention in neuroimaging studies of schizophrenia (Shenton, et al., 2001). However, among studies where gray matter volumes of the entire parietal lobe or of specific components of it were assessed in individuals with schizophrenia, the slight majority (60%) reported significant reductions in parietal gray matter volumes (Shenton et al., 2001). In two studies where diffusion tensor imaging was used to estimate fractional anisotropy (FA) as an index of the integrity of arcuate fasciculus in subjects with schizophrenia, one group found evidence of reduced FA (Burns et al., 2003), whereas the other group did not (Kubicki et al., 2005). Also, Hubl et al. (2004) reported a significant increase in FA was found in the lateral portion of the arcuate fasciculus in 13 individuals with schizophrenia with prominent auditory hallucinations when compared to 13 individuals with schizophrenia without prominent auditory hallucinations and to healthy individuals (Hubl et al., 2004). Finally, functional neuroimaging studies of the parietal cortex in individuals with schizophrenia support the critical involvement of this cortical region in working memory deficits (Barch and Csernansky, 2007).

While the bilateral cortical folding abnormality identified as significant in this study was restricted to a relatively small strip of parietal cortex, our results also indicate a broader pattern of bilaterally symmetric group differences in sulcal depth, especially in occipital, parietal, and temporal cortex. These results indicate that a number of subtle abnormalities of cortical folding may occur in schizophrenia. Other approaches have been used in the past to search for abnormalities in the patterning of cortical gyri and sulci in subjects with schizophrenia (Kikinis et al., 1994, Narr et al., 2004) and in subjects at high risk for developing schizophrenia (Jou et al., 2005), but these studies have reported evidence for both increased (Narr et al., 2004) and decreased cortical folding (Jou et al., 2005), as well as for a reorientation of the patterning of cortical folds (Kikinis et al., 1994) (i.e., from horizontal towards vertical). Also, Wisco et al. (2007) recently reported a significant shape difference in the pars triangularis of the left inferior frontal gyrus in individuals with schizophrenia after registering them to the FreeSurfer surface-based atlas. While we did not find a significant depth differences in this region, there was a hint that this region may not be as asymmetric in the schizophrenia group as in the comparison group (Fig. 1). This warrants further analysis using surface-based analysis methods that complement and extend those used in the present study.

Acknowledgments

This research was supported by PHS grants P50 MH071616 (Conte Center for the Neuroscience of Mental Disorders at Washington University School of Medicine); R01 MH058564; and the Human Brain Project (NIMH, NSF, NCI, NLM, NASA). The authors would like to thank the Conte Center Administration and Assessment Core for performing all clinical and cognitive assessments; the Biostatistics and Data Management Core for assistance with data management and analysis; John Harwell for software development; and Erin Reid for data analysis.

References

- Andreasen, N.C., 1983. The Scale for the Assessment of Negative Symptoms (SANS). The University of Iowa, Iowa City, Iowa.
- Andreasen, N.C., 1984. The Scale for the Assessment of Positive Symptoms (SAPS). The University of Iowa, Iowa City, Iowa.
- Andreasen, N.C., Arndt, S., Alliger, R., Miller, D., Flaum, M., 1995. Symptoms of schizophrenia. Methods, meanings and mechanisms. *Arch. Gen. Psychiatry* 52, 341–351.
- Anticevic, A., Dierker, D.L., Gillespie, S.K., Repovs, G., Csernansky, J.B., Van Essen, D.C., Barch, D.M., 2008. Comparing surface-based and volume-based analyses of functional neuroimaging data in patients with schizophrenia. *NeuroImage* 41, 835–848.
- Arnold, S.E., Talbot, K., Hahn, C.G., 2005. Neurodevelopment, neuroplasticity, and new genes for schizophrenia. *Prog. Brain Res.* 147, 319–345.
- Barch, D.M., Csernansky, J.G., 2007. Abnormal parietal cortex activation during working memory in schizophrenia: verbal phonological coding disturbances versus domain-general executive dysfunction. *Am. J. Psychiatry* 164, 1090–1098.
- Buckner, R.L., Head, D., Parker, J., Fotenos, A.F., Marcus, D., Morris, J.C., Snyder, A.Z., 2004. A unified approach for morphometric and functional data analysis in young, old, and demented adults using automated atlas-based head size normalization: reliability and validation against manual measurement of total intracranial volume. *NeuroImage* 23, 724–738.
- Burns, J., Job, D., Bastin, M.E., Whalley, H., Macgillivray, T., Johnstone, E.C., Lawrie, S.M., 2003. Structural disconnectivity in schizophrenia: a diffusion tensor magnetic resonance imaging study. *Br. J. Psychiatry* 182, 439–443.
- Courchesne, E., Press, G.A., Yeung-Courchesne, R., 1993. Parietal lobe abnormalities detected with MR in patients with infantile autism. *Am. J. of Roentgenology* 160, 387–393.
- Csernansky, J.G., Wang, L., Joshi, S.C., Ratnanather, J.T., Miller, M.I., 2004. Computational anatomy and neuropsychiatric disease: probabilistic assessment of variation and statistical inference of group difference, hemispheric asymmetry, and time-dependent change. *NeuroImage* 23 (Suppl 1), S56–S68.
- DeQuardo, J.R., Keshavan, M.S., Bookstein, F.L., Bagwell, W.W., Green, W.D., Sweeney, J.A., Haas, G.L., Tando, n R., Schooler, N.R., Pettegrew, J.W., 1999. Landmark-based morphometric analysis of first-episode schizophrenia. *Biol. Psychiatry* 45, 1321–1328.
- Dierker, D., Nordahl, C., Mostafavi, I., Schumann, C., Rivera, S., Amaral, A., Van Essen, D., 2007. Cortical folding abnormalities in autism revealed by surface-based morphometry. 13th Annual meeting of the Organization for Human Brain Mapping. Chicago, IL.
- Eickhoff, S.B., Amunts, K., Mohlberg, H., Zilles, K., 2006a. The human parietal operculum. II. Stereotaxic maps and correlation with functional imaging results. *Cereb. Cortex* 16, 268–279.

- Eickhoff, S.B., Schleicher, A., Zilles, K., Amunts, K., 2006b. The human parietal operculum. I. Cytoarchitectonic mapping of subdivisions. *Cereb. Cortex* 16, 254–267.
- First, M.G., Spitzer, R.L., Gibbon, M., Williams, J.B.W., 1995. Structured Clinical Interview for DSM-IV Axis I Disorders – Patient Edition (SCID-I/P). Biometrics Research Department, New York State Psychiatric Institute, New York.
- Hubl, D., Koenig, T., Strik, W., Federspiel, A., Kreis, R., Boesch, C., Maier, S.E., Schroth, G., Lovblad, K., Dierker, T., 2004. Pathways that make voices: white matter changes in auditory hallucinations. *Arch. Gen. Psychiatry* 61, 658–668.
- Jou, R.J., Hardan, A.Y., Keshavan, M.S., 2005. Reduced cortical folding in individuals at high risk for schizophrenia: a pilot study. *Schizophr. Res.* 75, 309–313.
- Kikinis, R., Shenton, M.E., Gerig, G., Hokama, H., Haimson, J., O'Donnell, B.F., Wible, C.G., McCarley, R.W., Jolesz, F.A., 1994. Temporal lobe sulco-gyral pattern anomalies in schizophrenia: an in vivo MR three-dimensional surface rendering study. *Neurosci. Lett.* 182, 7–12.
- Kippenhan, J.S., Olsen, R.K., Mervis, C.B., Morris, C.A., Kohn, P., Meyer-Lindenberg, A., Berman, K.F., 2005. Genetic contributions to human gyrification: sulcal morphometry in Williams syndrome. *J. Neurosci.* 25, 7840–7846.
- Kozlovsky, N., Belmaker, R.H., Agam, G., 2002. GSK-3 and the neurodevelopmental hypothesis of schizophrenia. *Eur. Neuropsychopharmacol.* 12, 13–25.
- Kubicki, M., Park, H., Westin, C.F., Nestor, P.G., Mulkern, R.V., Maier, S.E., Niznikiewicz, M., Connor, E.E., Levitt, J.J., Frumin, M., Kikinis, R., Jolesz, F.A., McCarley, R.W., Shenton, M.E., 2005. DTI and MTR abnormalities in schizophrenia: analysis of white matter integrity. *Neuroimage* 26, 1109–1118.
- Kuperberg, G.R., Broome, M., McGuire, P., David, A., Eddy, M., Goff, D.C., West, W.C., van der Kouwe, A.J.W., Salat, D.H., Dale, A.M., Fischl, B., 2003. Regionally specific thinning of the cerebral cortex in schizophrenia. *Arch. Gen. Psychiatry* 60, 878–888.
- Lewis, D.A., Lieberman, J.A., 2000. Catching up on schizophrenia: natural history and neurobiology. *Neuron* 28, 325–334.
- Marslen-Wilson, W.D., Tyler, L.K., 2007. Morphology, language and the brain: the decompositional substrate for language comprehension. *Philos. Trans. R. Soc. Lond. B. Biol. Sci.* 362, 823–836.
- Mesulam, M.M., 1998. From sensation to cognition. *Brain* 121, 1013–1052.
- Narayan, V.M., Narr, K.L., Kumari, V., Woods, R.P., Thompson, P.M., Toga, A.W., Sharma, T., 2007. Regional cortical thinning in subjects with violent antisocial personality disorder or schizophrenia. *Am. J. Psychiatry* 164, 1418–1427.
- Narr, K.L., Bilder, R.M., Kim, S., Thompson, P.M., Szeszko, P., Robinson, D., Luders, E., Toga, A.W., 2004. Abnormal gyral complexity in first-episode schizophrenia. *Biol. Psychiatry* 55, 859–867.
- Narr, K.L., Toga, A.W., Szeszko, P., Thompson, P.M., Woods, R.P., Robinson, D., Sevy, S., Wang, Y.P., Schrock, K., Bilder, R.M., 2005. Cortical thinning in cingulate and occipital cortices in first episode schizophrenia. *Biol. Psychiatry* 58, 32–40.
- Nichols, T.E., Holmes, A.P., 2002. Nonparametric permutation tests for functional neuroimaging: a primer with examples. *Hum. Brain. Mapp.* 15 (1), 1–25.
- Nordahl, C.W., Dierker, D., Mostafavi, I., Schumann, C.M., Rivera, S.M., Amaral, D.G., Van Essen, D.C., 2007. Cortical folding abnormalities in autism revealed by surface-based morphometry. *J. Neurosci.* 27, 11725–11735.
- Piven, J., Berthier, M.L., Starkstein, S.E., Nehme, E., Pearlson, G., Folstein, S., 1990. Magnetic resonance imaging evidence for a defect of cerebral cortical development in autism. *Am. J. Psychiatry* 147, 734–739.
- Rapoport, J.L., Addington, A.M., Frangou, S., Psych, M.R.C., 2005. The neurodevelopmental model of schizophrenia: update 2005. *Mol. Psychiatry* 10, 434–449.
- Rastogi-Cruz, D., Csernansky, J.G., 1997. Clinical rating scales. In: Guze, S.B. (Ed.), *Adult Psychiatry*. Mosby, Inc., St. Louis, pp. 45–52.
- Saad, Z.S., Reynolds, R.C., Argall, R.C., Japee, S., Cox, R.W., 2004. SUMA: an interface for surface-based intra- and inter-subject analysis with AFNI. Proceedings of the 2004 IEEE International Symposium on Biomedical Imaging, pp. 1510–1513.
- Shenton, M.E., Dickey, C.C., Frumin, M., McCarley, R.W., 2001. A review of MRI findings in schizophrenia. *Schizophr. Res.* 49, 1–52.
- Shibasaki, H., 2004. Central mechanisms of pain perception. *Suppl. Clin. Neurophysiol.* 57, 39–49.
- Talairach, J., Tournoux, P., 1988. Co-planar stereotaxic atlas of the human brain: 3-dimensional proportional system: an approach to cerebral imaging. G. Thieme, Thieme Medical Publishers, Stuttgart, New York.
- Thompson, P.M., Schwartz, G., Lin, R.T., Kan, A.A., Toga, A.W., 1996. Three-dimensional statistical analysis of sulcal variability in the human brain. *J. Neuroscience* 16, 4261–4274.
- Thompson, P.M., MacDonald, D., Mega, M.S., Holmes, C.J., Evans, A.C., Toga, A.W., 1997. Detection and mapping of abnormal brain structure with a probabilistic atlas of cortical surfaces. *J. Comp. Asst. Tomography* 21, 567–581.
- Toro, C.T., Deakin, J.F.W., 2006. Adult neurogenesis and schizophrenia: a window on abnormal early brain development? *Schizophr. Res.* 90, 1–14.
- Van Essen, D.C., 2005. A population-average, landmark and surface-based (PALS) atlas of human cerebral cortex. *NeuroImage* 28, 635–662.
- Van Essen, D.C., Dierker, D., 2007. On navigating the human cortex. *NeuroImage* 37, 1050–1054.
- Van Essen, D.C., Dickson, J., Harwell, J., Hanlon, D., Anderson, C.H., Drury, H.A., 2001. An integrated software system for surface-based analyses of cerebral cortex. *J. Am. Med. Inform. Assoc.* 8, 443–459.
- Van Essen, D.C., Dierker, D., Snyder, A.Z., Raichle, M.E., Reiss, A.L., Korenberg, J., 2006. Symmetry of cortical folding abnormalities in Williams syndrome revealed by surface-based analyses. *J. Neurosci.* 26, 5470–5483.
- Wisco, J.J., Kuperberg, G., Manoach, D., Quinn, B., Busa, E., Fischl, B., Heckers, S., Sorensen, A.G., 2007. Abnormal cortical folding patterns within Broca's area in schizophrenia: evidence from structural MRI. *Schizophr. Res.* 317–327.
- Zhou, Y.D., Ardestani, A., Fuster, J.M., 2007. Distributed and associative working memory. *Cereb Cortex* Epub ahead of print - PMID: 17615249.